Get your ticket now for BSAVA Congress 2022!

22 modules

100+ hours of CPD

50+ world class speakers

BSAVA will return live and face-to-face at **Manchester Central 24-26 March 2022**, delivering a brand-new style of learning across a refreshed interactive CPD programme, and an industry-wide exhibition – all under one roof.

And with the success of our 2021 Virtual Congress, we are delighted to announce the return of our **interactive virtual learning platform** running alongside the face-to-face event.

Don't miss out, get your ticket now!

www.bsavaevents.com/bsavacongress2022

GREAT BRITAIN & NORTHERN IRELAND

THANKS TO OUR PARTNERS

DIAMOND

VetPlus – A Global Leader in Veterinary Nutraceuticals

PLATINUM+

vetoquinol – ACHIEVE MORE TOGETHER

zoetis

PLATINUM

ROYAL CANIN – INCREDIBLE IN EVERY DETAIL

IDEXX

GOLD

BURTONS – The Home Of Veterinary Equipment

Hill's – Transforming Lives

ORION PHARMA – ANIMAL HEALTH

SUMMIT

Vets4Pets – Your Practice. Our Support.

SILVER

tvm

Vetsnow

docsinnovent

J.A.K Marketing Ltd

IMS

imv imaging

IVC EVIDENSIA

Boehringer Ingelheim

TECHNIK

Burgess

vetPartners

KatKin

BRONZE

nutravet

IM3

AWV

STORZ

VETCT

MILLPLEDGE VETERINARY

MEDIMARK SCIENTIFIC

VirtualRecall

Protexin veterinary

Eickemeyer

NationWide

BOVA

Dechra

KRUUSE

VDS

Vi Veterinary

VDS

Petplan

MAI

BSAVA BRITISH SMALL ANIMAL VETERINARY ASSOCIATION

CASE REPORT

Contrast-enhanced magnetic resonance angiography of patent ductus arteriosus in a dog

Gadolinium-enhanced three-dimensional magnetic resonance angiography is a relatively new technique in the veterinary field. A mature dog with suspected patent ductus arteriosus underwent contrast-enhanced magnetic resonance angiography at 1·0 T with a three-dimensional fast low-angle shot (FLASH) gradient-echo technique. Qualitatively, three-dimensional images of the ductus were particularly clear with surface reconstructions, and ductus diameters were easy to assess in native images. Contrast-enhanced magnetic resonance angiography is a fast, relatively non-invasive procedure that could be particularly useful when non-surgical interventional procedures are anticipated for ductus occlusion.

A. Louvet†,*, A. C. Duconseille* and P. Lazard†

Journal of Small Animal Practice (2010) **51**, 451–453

DOI: 10.1111/j.1748-5827.2010.00970.x

Accepted: 23 April 2010

†Small Animal Veterinary Clinic, 80 rue Pereire Saint Germain en Laye 78100, France

*Centre d'Imagerie par Résonance Magnétique de l'Animal (CIREN), 80 rue Péreire, Saint Germain en Laye, France

INTRODUCTION

Patent ductus arteriosus (PDA) is one of the three most common congenital heart defects identified in dogs and is the most commonly diagnosed correctable congenital heart defect in dogs (Kittleson 1998). Two-dimensional (2D) and colour-Doppler echocardiography are often sufficient to confirm the presence of a PDA. When surgical ligation is the chosen corrective procedure, precise measurement of PDA is often unnecessary. However, as interventional therapy becomes more widespread, knowledge about precise PDA dimensions is increasingly important (Saunders and others 2007).

CASE HISTORY

A VI/VI systolo-diastolic heart murmur was detected in a nine-year-old, spayed, female miniature poodle during a routine consultation. No abnormalities were detected on physical examination apart from the murmur. A colour Doppler-flow study confirmed continuous, high velocity, systolo-diastolic disturbed flow within the main pulmonary artery, but precise measures of ductus diameters were judged impossible with transthoracic ultrasound. The owner was reluctant to allow the proposal of surgical treatment and interventional shunt embolisation. To obtain a comprehensive anatomical description of the suspected extracardiac vascular anomaly, contrast-enhanced magnetic resonance angiography (CE-MRA) of the heart and associated great vessels were performed using a 1·0 T instrument (Magnetom Harmony; Siemens medical solutions, Erlangen, Germany) with high gradient strength (33 mT/m). An initial non-enhanced fast low-angle shot (FLASH) 3D gradient-echo sequence in the dorsal plane was performed with the dog in recumbency. Breath-hold, gadolinium-enhanced [0·2 mmol/kg (Dotarem, Guerbet, Roissy, France)], 3D MRA was then acquired in the same plane and with the same parameters. The contrast-enhanced sequence was subtracted from the pre-contrast dataset. Maximum intensity projection (MIP) and multiplanar reformations (MPR) were evaluated on the embedded Siemens workstation. Surface and volume rendering images were reviewed using commercially available software (OsiriX Imaging software).

A PDA was clearly visualised on the native images as well as in the MIP and MPR datasets (Fig 1). In the native images, the maximum ductal diameter at the aortic opening was 7 mm, and 6·9 mm at the pulmonary artery termination. The length of the ductus was 8 mm. Combining 3D reconstructions and surface and volume rendering techniques provided full data for evaluation of origin, termination and size of the duct (Fig 2).

Because these ductal diameters were a relative contra-indication to the use of detachable or free coils, but an ideal candidate for a more expensive Amplatzer duct occluder and all the more, because the general behaviour and exercice tolerance were considered normal, the owner declined for the present further interventional treatment.

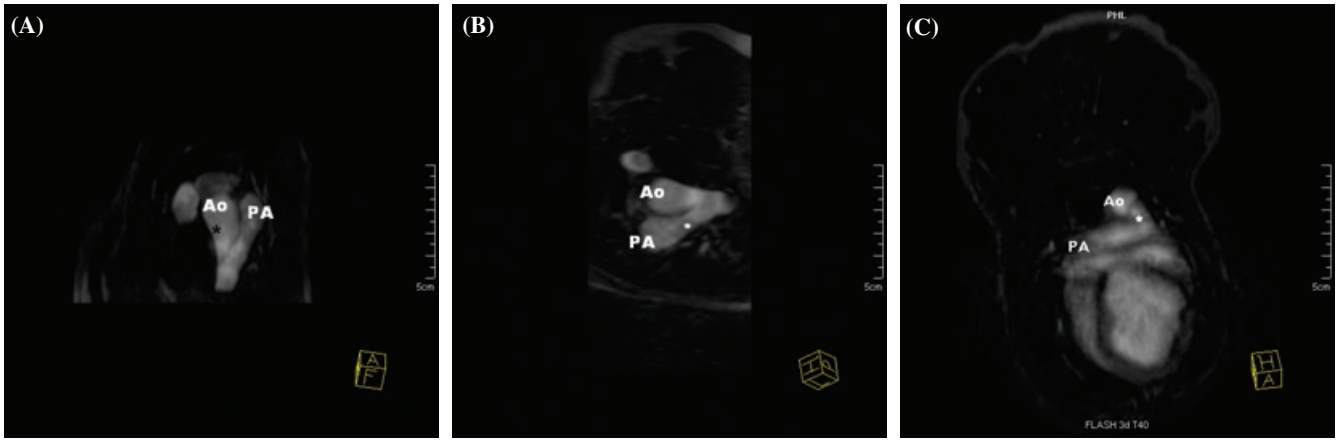

Fig 1. Subvolume maximum intensity projection image derived from the 3D TI-weighted (FLASH) sequence in the axial plane (A) centred at the level of the great vessels showing the aortic origin(Ao) of the ductus (asterisk); PA, pulmonary artery. In the sagittal plane (B), aligned with the long axis of the ductus, its pulmonary artery termination (PA) is clearly seen; Ao, descending aorta. In the dorsal plane (C), the ductus (asterisk) is visualized in its small axis between the descending aorta dorsally (Ao) and the right pulmonary artery (PA) ventrally. Slab thickness, 72 mm, TR/TE, 4.4/1.5 msec; flip angle, 30°; bandwidth, 455 Hz per pixel. The matrix was 137 × 192 (phase encoding from right to left × frequency encoding form ventral to dorsal), FOV of 143 × 191 mm. In-plane spatial resolution was 1 × 1 × 1 mm. One excitation was acquired and acquisition time was 33 sec.

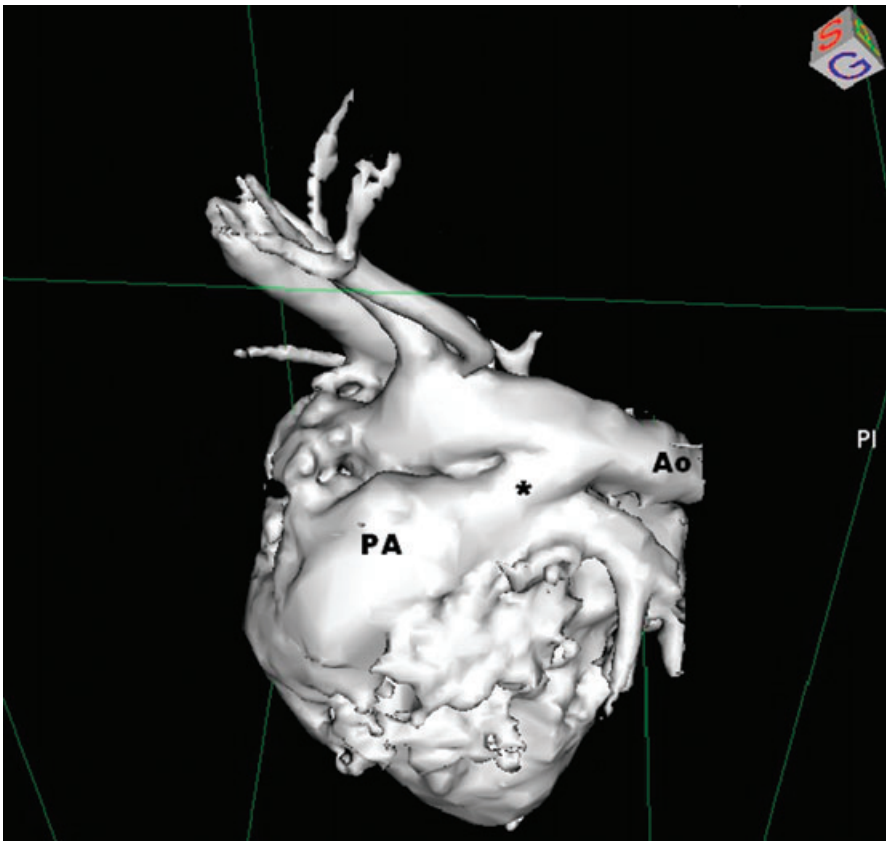

Fig 2. Surface rendering image derived from the 3D T1-weighted (FLASH) sequence of the heart of a dog with patent ductus arteriosus. The ductus (asterisk) is clearly seen connecting the descending aorta dorsally to the main pulmonary artery ventrally just below its right and left seperation.

DISCUSSION

In human beings, magnetic resonance imaging is frequently used to evaluate cardiovascular shunt lesions and has been proved more precise than either echocardiography or angiography for anatomic shunt delineation (Wang and others 2003). One of the most important advantages of 3D CE-MRA is the ability to process the images offline and to reformat angiographic-like projections in any arbitrary plane. This capability, provided by the 3D nature of the data, allows for evaluation of tortuous blood vessels and for understanding of their spatial relationships with neighbouring nonvascular structures (Hartnell and others 1996, Greil and others 2002). Three-dimensional images showing the anatomy of the PDA and its spatial relation to adjacent structures provide invaluable information for interventional cardiologists. CE-MRA in veterinary medicine has already been reported (Cavrenne and Mai 2008, Sager and others 2009, Bruehschwein and others 2010) and MRA of the normal canine heart and associated blood vessels has recently been described (Contreras and others 2008). However, there is, currently, no report of CE-MRA assessment of congenital cardiac disease in the dog or cat (Gilbert and others 2009). In human beings, images of aortic root and sinuses may be subject to blurring when conventional, non-ECG-gated MRA is used as a result of cardiac motion. It has been shown that ECG gating did provide a significant increase in the sharpness of images of the ascending thoracic aorta (Groves and others 2007). Although it was not performed in this case, future studies assessing the addition of cardiac gating for the detection of thoracic vessel disease have to be performed.

In conclusion, 3D CE-MRA offers an additional non-invasive method

of PDA examination especially when transthoracic echocardiography is unable to provide precise measurements of the duct and most importantly from the moment that an interventional procedure is anticipated. The wide field of view, multiplanar imaging and the ability to reconstruct complicated anatomical information in 3D are valuable attributes of MR angiography.

Conflict of interest

None of the authors of this article has a financial or personal relationship with other people or organisations that could inappropriately influence or bias the content of the paper.

References

Bruehschwein, A., Foltin, I., Flatz, K., Zoellner, M. & Matis, U. (2010) Contrast-enhanced magnetic resonance angiography for diagnosis of portosystemic shunts in 10 dogs. *Veterinary Radiology & Ultrasound* **51**, 116-121

Cavrenne, R. & Mai, W. (2008) Time-resolved contrast-enhanced MRA in normal dogs. *Veterinary Radiology & Ultrasound* **50**, 58-64

Contreras, S., Vazquez, J. M., Demiguel, A., Morales, M., Gil, F., Lopez, O. & Arencibia, A. (2008) Magnetic resonance angiography of the normal canine heart and associated blood vessels. *The Veterinary Journal* **78**, 130-132

Gilbert, S. H., Mc Connell, F. J., Holden, A. V., Sivananthan, M. U. & Dukes-Mc Ewan, J. (2009) The potential role of MRI in veterinary clinical radiology. *The Veterinary Journal* **183**, 124-134

Greil, G. F., Powel, A. J., Gildein, H. P. & Geva, T. (2002) Gadolinium-enhanced three dimensional magnetic resonance angiography of pulmonary and systemic venous anomalies. *Journal of the American College of Cardiology* **39**, 335-341

Groves, E. M., Bireley, W., Dill, K., Carroll, T. J. & Carr, J. C. (2007) Quantitative analysis of ECG-gated high resolution contrast-enhanced MR angiography of the thoracic aorta. *American Journal of Roentgenology* **188**, 522-528

Hartnell, G. G., Cochen, M. C., Meier, R. A. & Finn, J. P. (1996) Magnetic resonance angiography demonstration of congenital heart disease in adults. *Clinical Radiology* **51**, 851-857

Kittleson, M. D. (1998) Patent ductus arteriosus. In: Small Animal Cardiovascular Medicine. Eds M. D. Kittleson and R. D. Kienle. Mosby, St Louis, MO, USA. pp 218-230

Sager, M., Assheuer, J., Trummler, H. & Moormann, K. (2009) Contrast enhanced magnetic resonance angiography (CE-MRA) of intra- and extra-cranial vessels indogs. *The Veterinary Journal* **179**, 92-100

Saunders, A., Miller, M. W., Gordon, S. G. & Bahr, A. (2007) Echocardiographic and angiographic comparison of ductal dimensions in dogs with patent ductus arteriosus. *Journal of Veterinary Internal Medicine* **21**, 68-75

Wang, Z. J., Reddy, G. P., Gotway, M. B., Yeh, B. M. & Higgins, C. B. (2003) Cardiovascular shunts: MR imaging evaluation. *Radiographics* **23**, S181-S194